

Gain 2 CET credits – enter online at www.otcet.co.uk or by post

Keratoconus: Diagnosis, contact lens fitting and management

Waheeda Illahi PhD, MSc, BSc(Hons), MCOptom



CONFUSED ABOUT CET REQUIREMENTS?

See www.cetoptics.com/cetusers/faqs/

IMPORTANT INFORMATION

Under the new Vantage rules, all OT CET points awarded will be uploaded to its website by us. All participants must confirm these results on www.cetoptics.com so that they can move their points from the "Pending Points record" into their "Final CET points record". Full instructions on how to do this are available on their website.



Module 5 Part 2 PAYL

About the author

Waheeda Illahi is Deputy Head of Department, Birmingham & Midland Eye Centre. She has ten years' experience in specialised hospital contact lens fitting and a PhD on keratoconus.

Contact lenses were first used in connection with keratoconus over 120 years ago.¹ Lens designs and materials have changed significantly over the years and are continuing to develop. The prime focus of contact lenses for keratoconus remains unchanged over time: to improve vision, provide a comfortable, stable mode of visual rehabilitation and, maintain the health and integrity of the cornea. Before attempting to fit and manage the keratoconic patient, both appropriately and with confidence, the clinician should have an understanding; first of the disease condition and second, of general characteristics observed in these patients.

It is hoped that practitioners who are not already involved in managing keratocopic patients would consider exploring this incredibly rewarding area of work.

Keratoconus is a non-inflammatory corneal thinning disorder which results in a conical protrusion of the cornea. Mild to marked impairment of vision occurs, depending on the extent of induced irregular astigmatism, myopia and protrusion.² Keratoconus is usually bilateral but asymmetrical between the two eyes. However up to 15% of reported cases are unilateral.^{3,4,5} The onset of keratoconus is usually at puberty and the condition tends to be progressive until the third or fourth decade of life. It usually arrests at this stage, but may adopt a variable pattern of progression.^{2,6}

Prevalence

Numerous studies have reviewed the prevalence of keratoconus. Estimates lie between 50 and 230 per 100,000 in the general population, approximately one per 2000.^{2,7,8} When considering the prevalence of keratoconus the differing diagnostic criteria used in different studies need to be taken into account. A much higher prevalence may be found as corneal topography is used more, thanks to its greater sensitivity as a diagnostic tool.

Racial factors as well as climatic conditions may play a role. In a Midlands study, Asian patients were noted to be younger at the time of diagnosis of the condition and had a fourfold increase in presentation com-

Signs	Symptoms
Scissors reflex (swirling retinoscopy reflex)	Frequently changing spectacle Rx and axis of astigmatism
Distorted/ irregular keratometer mires with steep readings	Poor repeatability of subjective refraction
Prominent corneal nerves	Ghosting/ monocular diplopia Glare at night Haloes around lights Blurred/ distorted vision

Table 1. Diagnostic criteria associated with early keratoconus

pared to white patients.⁹ A relatively high incidence has been documented in the Mediterranean and Middle Eastern areas; a relatively lower incidence has been reported in places such as Japan, Taiwan and Singapore.^{10,11,12} Males may be at higher risk than females. In addition, the prevalence of the condition is about 7% in Down's syndrome.⁷

Various studies have looked at personality traits in keratoconus. Increased rates of schizophrenia and phobias have been reported in keratoconic males compared to normals, whereas keratoconic females have shown increased rates of depression.¹³ A more recent study looked at obsessiveness and a range of personality traits in keratoconics and in myopes of at least -6.00 D.Sph. who wore hard contact lenses. No significant differences were found between the two groups in terms of these personality traits.¹⁴

Early stages

The diagnostic criteria in table 1 are not unique to keratoconus but should raise suspicion, especially in the presence of myopic astigmatism.

In the early stages of the condition, before the cornea starts to protrude, keratometric readings may not necessarily show steep values. Patients may be asymptomatic.

Eyes which have good spectacle visual acuity and show no signs of keratoconus on slit lamp examination, have been described as a 'forme fruste' of keratoconus or a variant of the normal.¹⁵ Corneal nerves are visible in the normal cornea; however in keratoconus the nerve fibres may be more visible because nerve fibre thickening has been noted to occur in association with changes in Bowman's layer and the keratocytes.¹⁶ This nerve fibre thickening has been found to occur in the sub-basal plexus layer.

In moderate to advanced keratoconus, slit lamp findings may show clinical changes.

When fitting keratoconic patients with contact lenses, it is very important to carry out a thorough slit lamp examination and record all the clinical features, such as areas of staining, as this record will enable further changes to be documented.

It is also important to note that the intraocular pressure measured by applanation tonometry is lower in keratoconus

Clinical Sign	Description	Method of examination
Corneal nerves	More prominent than in normal eye	Slit lamp
Vogt's striae ¹⁷	Fine vertical lines in the stroma and Descemet's membrane, usually parallel to the steep axis of the cone, disappear temporarily on digital pressure.	Slit lamp (Optical section)
Fleischer's ring ¹⁸	Iron pigment ring forms the base of the cone. May be partial or complete. Yellow-brown in colour, this depends on the amount of ferritin deposited in the basal epithelial layer	Slit lamp Cobalt blue filter. Diffuse illumination ¹⁹
Corneal thinning	Corneal thinning and cone displacement is visible in the central-inferior region in moderate and advanced keratoconus.	Slit lamp Optical section. High Magnification.
Munson's sign	Ectatic protrusion of the cornea on downgaze produces a V-shaped conformation of the lower lid.	Slit lamp/ Burton lamp/ unaided
Rizzuti's sign ²⁰	Lateral illumination of the cornea produces a steeply focused beam of light near the limbus. Moderate: beam central to limbus. Advanced: beam displaced peripherally.	Slit lamp. Lateral illumination

Table 2. Clinical signs, description and method of examination

patients compared to normals.¹⁹

Early keratoconus

As the cone develops, the epithelium can be seen to be thinned, and enlarged superficial epithelial cells may be observed on specular microscopy.^{21,22} Extracellular and intercellular ferritin accumulate in the epithelium at the periphery of the cone, producing a Fleischer's ring.²³

In terms of the changes in the stromal layer, a reduction in the number of lamellae has been noted but no changes in the actual thickness of the collagen lamellae on examination of tissue by electron

microscopy.²⁴ Further studies, looking at the packing of fibrils in the stroma in order to explain stromal thinning, have found no difference in the interfibrillar spacing in the keratoconic cornea.²⁵

Changes such as ruptures or folds in Descemet's membrane have been noted as a common feature in keratoconus.²⁶ No real explanation has been found for these ruptures following studies of the extracellular matrix.^{27,28}

Eventually some form of corneal scarring is seen in patients with keratoconus. The scars may be small focal opacities, which may be sub-Bowman's or pre-Descemet's membrane. The small stromal scars may be a

Gain 2 CET credits – enter online at www.otcet.co.uk or by post

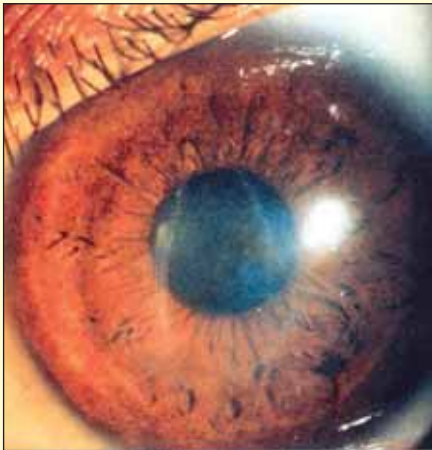

Figure 1. Moderate Keratoconus showing Vogt's striae (Courtesy BMEC)

result of repair of idiopathic breaks in Bowman's layer.

This type of corneal scarring is not thought to be related to contact lens wear. However, factors such as corneal staining, contact lens wear, Fleischer's ring, steeper corneas and increasing age have been associated with corneal scarring.²⁹

Hydrops

In more advanced cases of keratoconus which have been studied, acute hydrops will develop (Figure 2). In hydrops, marked stromal oedema occurs as a result of the endothelium and Descemet's membrane rupturing, allowing aqueous humour to enter the stroma. The oedema usually resolves over a period of time and eventually results in scarring. If this scarring is in the area of the visual axis then the visual acuity can decrease.

If, however, the scar is outside the area of the visual axis, the visual acuity may improve as the cone flattens after resolution of the hydrops.

In keratoconus, very rare cases have been reported where spontaneous rupture of the cornea has occurred.^{30,31} Hydrops is believed to occur either spontaneously or as a result of ocular trauma, for example where there is very vigorous eye rubbing, in 2-3% of patients with keratoconus.³² Various risk factors have been recognised which can result in corneal ectasias, including allergy and eye rubbing, and in those of a younger age and poor visual acuity at the time of diagnosis.^{30,32,33,34} The area of the cornea affected by hydrops can vary from 7% to 100% of the corneal surface and is thought to affect the duration of the dis-

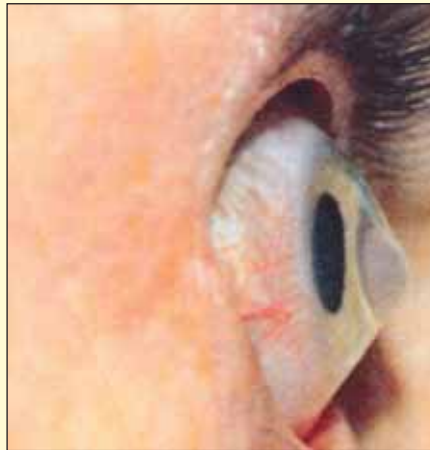

Figure 2. Corneal hydrops showing residual scarring (courtesy BMEC)

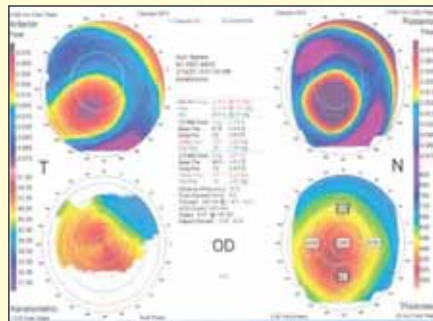


Figure 3. (Orbscan Map)

ease process and final visual acuity. Serious complications can arise, so that close observation is essential.³⁰

Three cases were presented in 2003 in which spontaneous hydrops led to perforation or imminent perforation which required penetrating keratoplasty to be carried out on an urgent basis. Two cases were associated with pellucid marginal degeneration and one with keratoconus. The keratoconic patient had no presenting history of trauma, eye-rubbing, or ocular allergy. The patient was treated with tissue adhesives and later had penetrating keratoplasty.³⁵

Associated conditions

Keratoconus has been associated with atopy, asthma³⁶ and eye rubbing.³⁷

Other conditions in which keratoconus has been noted include ocular rosacea, cone-rod dystrophy, and corneal granular dystrophy as well as a case of early onset of ectasia following laser in situ keratomileusis (LASIK).^{38,39,40,41}

Keratoconus has also been linked with systemic conditions such as Leber's congenital amaurosis, Down's syndrome, and mitral valve prolapse.⁷

It is important to note that all atopic con-

ditions will influence the success of contact lens wear in the keratoconic patient.

Pathogenesis

The cause of keratoconus is not yet known. More than one factor is believed to be involved. The epidemiology and biochemistry of keratoconus has been discussed in various review articles.^{2,7,42}

A working hypothesis for the cause of keratoconus has been suggested,⁴³ identifying various factors as involved in the process: a build-up of destructive aldehydes within the keratoconic corneas as well as abnormal processing of free radicals and peroxides; the process of apoptosis occurring in irreversibly damaged cells, wound healing or repair occurring in cells that are damaged reversibly; focal areas of corneal thinning and fibrosis occurring in areas of wound healing.

A genetic component in keratoconus is recognised^{44, 45} and its occurrence in monozygotic twins. There are reports of positive family history in 6-15% of cases.⁴⁶ In the absence of clinical signs, videokeratographic techniques can be used on affected family members.⁴⁷ An autosomal dominant mode of inheritance has been suggested with variable expression.^{2,48} The possibility of recessive inheritance has also been suggested.⁴⁹

On chromosome²¹, close to the centromere, a gene for an autosomal dominant form of keratoconus has been mapped.^{50,51} This provides an interesting link between keratoconus and trisomy.²¹ The incidence of keratoconus in Down's syndrome varies from 0.5-15% (that is, it is 10-300 times more common than in the general population).² Various studies have reported on the familial rate of keratoconus. A positive family history in 19%, 13.5% and 20% of cases has been reported.^{52,53}

Posterior keratoconus

A rarer form of the condition, posterior keratoconus, has been noted in the literature in the form of case reports.⁵⁴ In one case study, anterior keratoconus was noted in one eye and posterior keratoconus in the other eye.⁵⁵ A classification system was suggested on the basis of retrospective analysis of topographic maps which showed significant corneal surface changes. Uniform corneal steepening was noted in generalised posterior keratoconus and

Grade	Corneal radius of curvature (mm)	Equivalent dioptres
	8.00-7.00	42-48
Moderate	6.90-6.50	49-52
Moderate/Advanced	6.40-6.00	53-56
Advanced	<6.00	<56

Table 4. Classification of keratoconus in terms of the radius of curvature of the anterior cornea.

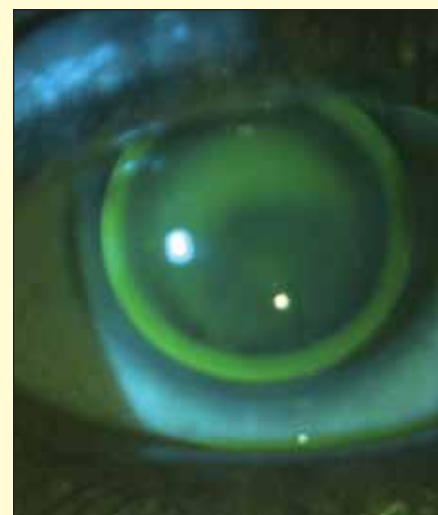

Figure 4. Three-point-touch (ideal fit)

corneal steepening was seen in localised central and paracentral posterior keratoconus, whereas corneal flattening was seen in cases of localised peripheral posterior keratoconus.⁵⁶

Corneal topography

Corneal topography is a very useful aid in the diagnosis of keratoconus, especially in the absence of clinical signs.

Caution, must, however, still be exercised as dry-eyed patients with aqueous tear deficiency and chronic drying of the ocular surface can exhibit changes similar to those seen in keratoconus; that is, inferior corneal steepening and high astigmatism.

In the basic Orbscan height maps, a mean radius of curvature of the corneal surface (best fitting sphere, BFS) is calculated and a relative height above or below this ideal best-fitting spherical surface is shown. Hence, the curvature of the cornea at any point is not shown. Warm colours show areas which are higher than the BFS and cooler colours which are lower than the BFS. The most appropriate colour-coded scale for anterior and posterior maps of the Orbscan system was proposed to be the 10 μ m and 20 μ m interval scale.⁵⁷ It has been suggested that an Orbscan map be classified as abnormal if three or more colours are found within the central 3mm area.

Figure 3 shows an Orbscan map of a keratoconic eye. The maps shown are (top left) departures of anterior surface from best sphere (top right) departure of posterior surface from best fit sphere (bottom left) keratometry map (bottom right) pachymetry map. The scale is located in the left hand

side and can be altered. Note the elevated heights, surface steepening and thinning that occurs at the apex of the keratoconic cone.

Pachymetry

Corneal thickness measurement provides additional information when diagnosing and assessing keratoconus. There are various different methods for assessing corneal thickness, including ultrasound.⁵⁸ Ultrasonic pachymetry (US) is currently accepted as the 'gold standard' when assessing the thickness of the cornea.⁵⁹ But it has the disadvantage of involving the use of a local anaesthetic and contact with the cornea. It can also be difficult to locate the exact point on the cornea accurately when serial examinations are required.⁶⁰ Optical pachymetry obviates direct contact, but this method has been shown to be less accurate, with a 10-100 μ m non-linear error.⁶¹

Table 3 summarises ultrasonic and Orbscan measurements of corneal thickness in normals and keratoconic patients from a study carried out at the Birmingham and Midland Eye Centre.

Management of keratoconus

Management of keratoconus varies considerably, depending on the contact lens service available to deal with moderate to advanced cases. In terms of the techniques used for fitting keratoconic patients, no single method or philosophy is best for all patients. There are no fixed rules for fitting keratoconus. A variation also exists in the design and types of lenses preferred by the major Hospital Eye Service (HES) referral

centres where many moderate/ advanced keratoconic patients are managed.

Numerous different classification systems have been suggested. Table 4 outlines a simple system based on the radius of curvature of the central cornea. Keratoconus cones can also be classified by shape and position.³⁴ This may be helpful when selecting the design of contact lens to fit the cornea. The suggested classes are:

- Nipple - small diameter (5mm); cone lies in the lower nasal quadrant within a few millimetres of the visual axis
- Oval - larger (>5mm); lies more commonly in the infero-temporal quadrant.
- Globus - largest diameter (>6mm); 75% of the cornea is effected.

Spectacles

Mild keratoconus can be corrected with spectacles. Retinoscopy is difficult; a normal subjective refraction is required. Monocular keratoconus is usually best dealt with using spectacle correction. In this group of patients, motivation for contact lens wear tends to be poor.

Contact lens options for keratoconus

When a keratoconic patient is no longer able to obtain good visual acuity as a result of increasing levels of irregular astigmatism and higher-order aberrations, rigid contact lenses will be required, effectively to provide a new anterior surface to the eye.⁶³

Contact lenses are considered when vision is not correctible to 6/9 by spectacles and patients become symptomatic.

Gain 2 CET credits – enter online at www.otcet.co.uk or by post

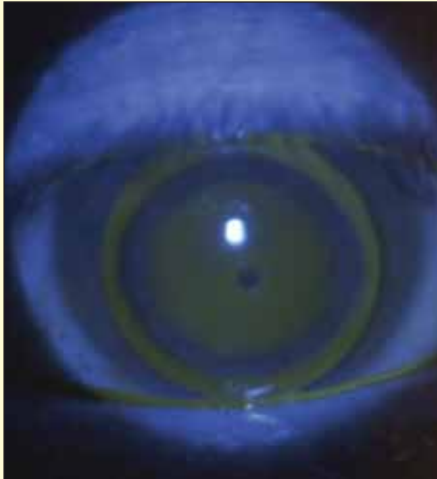


Figure 5. Steep fitting: this method may work for very small cones but is unsuitable for large, oval, sagging cones

There are many lens designs for keratoconus and it is difficult to predict which design will be suitable for any particular patient.

Rigid gas permeable lenses

Rigid gas permeable (RGP) corneal lenses are the lenses of first choice for correcting the irregular astigmatism which occurs as the cornea changes shape. The aim is to provide the best vision possible with the maximum comfort so that the lenses can be worn for a long period of time. A mid to high Dk/t material is preferred by the author as it provides the stability required for these high powered lenses. A balance is required between a material which is deposit resistant especially in patients who maybe atopic, and providing sufficient oxygen flux. Keratoconic patients tend to have long wearing times and usually become long-term lens wearers. In some cases it may become necessary for the contact lens practitioner to try several different materials for a patient who has poor wettability.

Fitting methods/philosophies

1) Three-point-touch design

The three-point-touch design is the most popular and the most widely fitted design for keratoconic patients. The aim is to distribute the weight of the contact lens as evenly as possible between the cone and the peripheral cornea. The ideal fit should show an apical contact area of 2-3mm with mid-peripheral contact annulus. The area and shape of the contact zones may be more variable as a result of cone asymmetry; a crescent shaped mid-

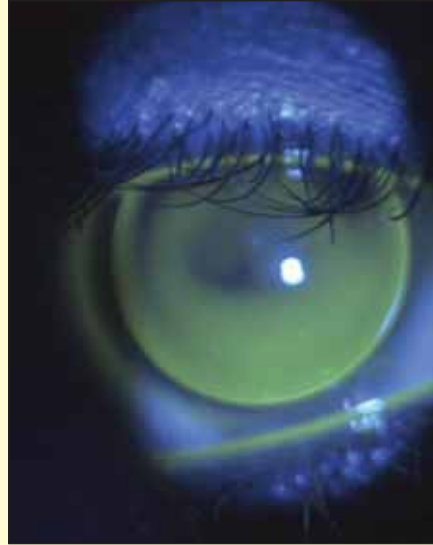


Figure 6. Flat fitting lens

periphery is quite acceptable. Adequate edge clearance is required to ensure tear exchange.

Three-point-touch actually refers to the area of apical central contact and two other areas of bearing or contact at the mid-periphery in the horizontal direction.

This type of fitting philosophy works very well for small central cones.

2) Apical clearance

In this type of fitting technique, the lens vaults the cone and clears the central cornea, resting on the paracentral cornea. This type of lens was suggested as it was argued that apical clearance would minimise trauma to the central cornea. These lenses tend to be small in diameter and have small optic zones; the small BOZD can result in glare problems. The potential advantages of reducing central corneal scarring are outweighed by the disadvantages of poor tear film, corneal oedema, and poor visual acuity as a result of bubbles becoming trapped under the lens.

3) Flat fitting

The flat fitting method places almost the entire weight of the lens on the cone. The lens tends to be held in position by the top lid. Good visual acuity is obtained as a result of apical touch. Wide edge stand-off cannot usually be eliminated. Alignment can be obtained in early keratoconus; however, flat fitting lenses can lead to progression/acceleration of apical changes and corneal abrasions. This type of fitting philosophy is useful where the apex of the cone is displaced.

Rigid gas permeable lens designs

There are numerous different designs available. A list follows of some of the designs commonly used by the author and colleagues.

Different types of RGP lens designs

Early keratoconus

Aspherics or multicurve lenses
Kera I and II (No.7)
Acuity K
Rose K (David Thomas)

Moderate keratoconus

Kera II
Quasar KNO7
Rose K (David Thomas)
Woodward KC3

Moderate/Advanced keratoconus

Kera II/III
Rose K (David Thomas)
Profile K (J Allen)

Advanced keratoconus

Large diameter lenses
S-Lim (J Allen)
Dyna-intra limbal (No.7)

Scleral lenses

PMMA
Gas permeable (Innovative Sclerals)

Aspheric lenses

Aspheric lenses flatten in curvature from the centre to the periphery. The eccentricity or 'e value' is independent of the base curve and determines the rate of flattening. Spherical lenses, on the other hand, have a constant radius of curvature in the optic zone and different curvatures cut into the lens in the peripheral areas.

The average cornea has an 'e value' of 0.65. Decreasing the lens 'e value' decreases the rate of flattening; increasing the 'e value' increases the rate of flattening. The aim of aspheric lens fit should be good centration, central alignment or slight central bearing, good movement (1mm), and peripheral clearance (0.5mm). Useful for oval type cones are aspheric lenses, for example the Quasar K (No.7 Contact Lens Laboratory) or the Persecon Elliptical K (Ciba Vision) older design.

Multicurve designs

All lens parameters are available from the manufacturers which make these lenses easy to fit. The Woodward C3K is a specialist design which can be used for moderate to advanced keratoconus.

Maguire lens system

This lens system is based on the Soper lens system, which is no longer used in the UK. The McGuire system was first introduced in 1978 and consists of three diagnostic lens sets, nipple, oval or globus (see cone classification). The optic zone sizes vary from 6mm for the nipple cone to 6.5mm for the oval cone, and 7mm for the Globus. The McGuire system has four peripheral curves; the secondary curve of the system is 0.5mm flatter than the central base curve. The third curve is 1mm flatter than the secondary curve. The fourth and final peripheral curve is 2mm flatter than the third curve.

Rose K

The Rose K is a unique keratoconus lens design with complex computer-generated peripheral curves based on data collected by Dr Paul Rose of Hamilton, New Zealand. The system (26 lens set) incorporates a triple peripheral curve system - standard, flat, steep - in order to order to achieve the ideal edge lift of 0.8mm.

The design starts with a standard 8.7mm diameter and works by decreasing the optic zone diameter as the base curve gets steeper. It is available in base curves of 4.75-8.8mm and diameters of 7.9-10.2mm. Toric curves are available on the front and back surfaces as well as in the periphery. The practitioner has a choice of peripheral curves.

Standard lift lenses should work 70% of the time. Peripheral curves can be configured to a toric design. Rose K lenses are very widely used.

Dyna IntraLimb (DIL), No.7 Contact Lens Laboratory

These lenses are useful when stability is required, especially in inferiorly displaced cones or in cases of pellucid marginal degeneration as well as post graft. A range of diameters is available (10.8mm to 12.5mm). High Dk materials are recommended.

Soft lenses

These (hydrogels, silicone hydrogels) have a

limited role in correcting corneal irregularity, as they tend to drape over the surface of the cornea and result in poor visual acuity. However, soft lenses designed specifically for keratoconus (eg Kerasoft) have a useful role in early keratoconus or where a patient may be intolerant of RGP. Soft lenses tend to be more comfortable compared with RGPs.

For example, Kerasoft Lenses (Ultravision) (58% water content terpolymer), which are available in four series, A,B,C and D, and Acuity K Mark I and II (Acuity Contact Lenses).

Advantages

1) They afford higher levels of comfort and longer wearing times, especially in patients intolerant of RGP corneal lenses or in monocular keratoconus.

2) They are useful where the cone apex may be displaced, especially if it is very low.

3) They are useful for certain groups of patients, for example airline pilots.

4) They are relatively simple to fit.

Disadvantages

1) Visual acuity may be variable in cases of very high minus lenses.

2) Low-powered diagnostic lenses may not provide an accurate guide to the fit of the final lens, which may be extremely high powered.

3) There may be reduced oxygen transmissibility and the risk of neovascularisation if the lenses are over-worn.

4) If the condition has progressed, it may be difficult to change to RGP's at a later stage.

Piggyback lenses

Piggyback lenses are used for difficult cases, for instance in cases of RGP lens intolerance, proud nebulae in keratoconus, or apical dimpling or where there are areas of recurrent epithelial erosion. The system consists of a rigid lens fitted on top of a soft lens. The aim is to maintain the same level of visual acuity as with a single lens.

The RGP lens should be fitted first. Good centration is important and a slightly larger area of apical touch is usually acceptable as the RGP lens will be cushioned by a soft lens. A silicone hydrogel soft lens should be used where possible, with good movement and coverage/ centration as in a normal soft lens fitting.

Caring for the two types of lenses can be

difficult long-term. Ideally, try to have the patient use the same care regime for the two lenses as this will make cleaning easier, or alternatively consider a disposable soft lens. The cornea should be observed carefully for dryness and neovascularisation.

Hybrid lens system

The Softperm lens (Ciba Vision) is a hybrid lens with a RGP centre surrounded by a soft hydrophilic skirt. These lenses tend to be used in cases of RGP lens intolerance. There are many advantages to the Softperm lens as it provides better comfort than the RGP lenses, better centration and reasonable visual acuity. In the HES, these lenses tend to be used only in exceptional cases because of the risk of induced corneal oedema and neovascularisation.

The main disadvantages of Softperm lenses are frequent breakage of the lens, giant papillary conjunctivitis and peripheral corneal neovascularisation.

It should be noted that the Softperm lens was not designed for keratoconus, but for a normal cornea. As it provides the comfort of a soft lens and visual acuity of a rigid lens it has been adopted by keratoconic patients who inevitably over-wear these lenses and end up with complications.

Scleral lenses

Scleral lenses play a very significant role in cases of advanced keratoconus where corneal lenses do not work and corneal surgery is contra-indicated. Scleral lenses completely neutralise any corneal irregularity and can help patients maintain a normal quality of life. A PMMA lens can be used in cases of scleral toricity.

PMMA scleral lenses are made by the impression method. This practice is confined to the HES. An impression is taken of the cornea, generally with alginate material (orthoprint) and a clear shell is made from poly-methyl methacrylate material. Optic curves are ground on to the shell. This can be done in-house or the shell can be sent to Cantor & Nissel. The shell is fenestrated, adjusted, and ground until a desirable fit is obtained. Once an acceptable fit is obtained the lens can be sent for working to the required power.

Advantages

Easy to insert and remove

Any type of corneal irregularity is corrected

Easy to store (dry)

Long life

Gain 2 CET credits – enter online at www.otcet.co.uk or by post**Disadvantages**

Much chair time is needed
A very specialised fitting technique

RGP sclerals

Ken Pullum (Innovative Sclerals) confirms that these lenses are fitted from a preformed design and lathe cut. These lenses are filled with saline and inserted. The aim is to obtain overall central clearance. These lenses have many applications.

Lens costs/prices

Prices of lenses vary significantly depending on the design and material. Lens manufacturers who offer exchange and three month warranty terms tend to charge a slightly higher price per lens. Practitioners would be well advised to invest time in making a "price list" before undertaking case work.

Preliminary examination

Many patients with keratoconus will be in their late teens or early twenties. They will need information and reassurance. They may present with concerns about the speed with which their vision has deteriorated. Quite often teenagers may be accompanied by their parents.

- It is important to explain the reason why the spectacle prescription has been changing rapidly over the past 12-24 months.
- The nature of the corneal thinning disorder and the reasons for corneal distortion should be explained. The advantages of contact lenses over spectacles should be emphasised.
- The progression of the condition and the prognosis should be discussed.
- An information leaflet explaining the condition, and information about the local keratoconus support group, should be provided.
- Any cost implications should be discussed.

Fitting protocol

1) After taking full history and symptoms, the preliminary examination should include age, occupation, and motivation.

Any history of previous contact lens intolerance or allergies should be noted.

2) Full slit lamp biomicroscopy is vital.

3) Examine the keratometer readings. The mires may be very distorted, however they provide useful information at the initial stage.

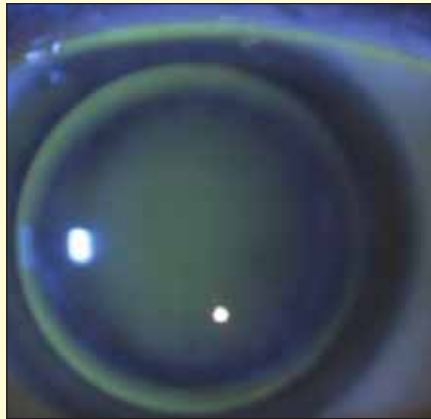


Figure 7. Normal fit

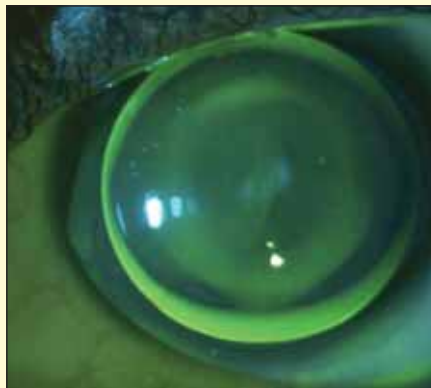

Figure 8. Keratoconic fit

4) Choose the correct base curve; start with the base curve equivalent to the steeper of the two keratometer readings. Many variations on this philosophy exist.

5) Allow the lens to settle for about 20 minutes before evaluating the fluorescein pattern.

6) Examine the central area, the mid peripheral area and the periphery.

7) Evaluate the lens in the central position. Once you have judged the fit, alter the fit as necessary (for example flatten, if pooling) until you obtain gentle apical touch and the three-point-touch. Use the Guillon grading scale for assessing the fluorescein picture.

There should be minimal bearing (touch) at the apex of the cone, as well as an area of bearing between the periphery of the lens and the intermediate zone of the cornea (Figure 4).

The lens should be ordered in mid-high Dk material after an over-refraction has been undertaken.

A collection appointment should be arranged. An aftercare appointment should follow four weeks after the collection appointment, when slight modifications may be necessary.

Normal lens (Figure 7) fit versus keratoconic fit. (Figures 8)

Normal fit

Good centration
Alignment/ slight pool on alignment
0.75 mm movement

Keratoconic fit

A whole range of acceptable fits. It may not be possible to obtain the ideal fit
Ensure the cornea is observed carefully

Cleaning regime

Soft and corneal lenses for keratonic patients do not require specialised regimes. Patients who suffer from GPC associated with keratoconus may need to use unpreserved solutions. Other eyedrops may be necessary.

RGP sclerals require a special cleaning protocol, which will be covered in a future series.

Conclusions

- Patients with keratoconus are a challenge
- Keratoconic patients require ongoing care
- A wide range of contact lens designs and materials is available
- Excellent technical support is usually available
- Keratoconics can live a normal life with the help of a good contact lens practitioner

Acknowledgments and disclaimer

The author does not have any personal interest in any of the products mentioned.

I would like to express very sincere thanks to Dr Sudi Patel for interesting discussions in relation to this article. Also many sincere thanks to Professor Neil Charman for supervising me through the fascinating journey of studying keratoconus.

The author would like to acknowledge all her colleagues at the Birmingham & Midland Eye Centre, and all the contact lens manufacturers/suppliers who agreed to allow discussion of their lenses, especially the information provided by technical advisors.

References

Visit www.optometry.co.uk/references

Gain 2 CET credits – enter online at www.otcet.co.uk or by post

Module questions

Course code: c-4088

Please note, there is only one correct answer. Enter online or by form provided.

- Which of the following statements is true?
 - The incidence of keratoconus has been documented to be higher in the Asian subcontinent.
 - The incidence of keratoconus has been documented to be higher in the Mediterranean and Middle Eastern countries.
 - The incidence of keratoconus has been documented to be lowest in European countries.
 - The incidence of keratoconus has been documented to be higher in Japan, Taiwan and Singapore.
- Which of the following statements is true?
 - Vogt's striae are fine vertical lines which occur in the stroma and Descemet's layer and do not disappear transiently on digital pressure?
 - Vogt's striae are fine vertical lines, which occur in the endothelial layer and disappear transiently on digital pressure?
 - Vogt's striae are fine vertical lines which occur in the stroma and Descemet's layer and disappear transiently on digital pressure?
 - Vogt's striae are fine vertical lines, which occur in the endothelial layer and disappear transiently on digital pressure?
- Which of the following statements is true?
 - Corneal hydrops is believed to occur either spontaneously or as a result of contact lens over-wear in 2-3% of keratoconic patients
 - Corneal hydrops usually resolves to leave a clear cornea
 - Corneal hydrops is believed to occur either spontaneously or as a result of ocular trauma e.g. eye rubbing in 2-3% of patients?
 - Corneal hydrops is a sign of early keratoconus?
- Which of the following statements is correct?
 - Corneal topography in keratoconus tends to produce central corneal steepening only
 - Nasal corneal steepening only?
 - Inferior corneal steepening and high astigmatism?
 - None of the above?
- Which of the following statements is true?
 - RGP corneal lenses are the lenses of first choice for fitting Keratoconus
 - Keratoconic patients should be corrected with spectacles in the early stages
 - Up to 15% of keratoconics have been reported to be monocular
 - All of the above
- Which of the following statements is true?
 - The nipple cones usually affects 75% of the cornea
 - Posterior keratoconus is a common form of keratoconus
 - Keratometry readings are usually more than 6.5mm in advanced keratoconus?
 - The oval cone lies more commonly in the inferotemporal quadrant?
- Which of the following statements is true?
 - The three-point touch fitting method aims to distribute the weight of the lens evenly between the cone and the peripheral cornea
 - The three-point touch philosophy works very well for small central cones
 - The three-point touch method should show an apical contact area of 2-3mm
 - All of the above
- Which of the following statements is true?
 - Apical clearance is a fitting method in which the lens rests on the paracentral cornea
 - Apical clearance is a fitting method in which there is a central contact area of 2-3mm
 - Apical clearance fitting method is suitable for large, oval sagging cones
 - The advantages of the apical clearance method outweigh the disadvantages
- Which of the following statements is false?
 - Flat fitting lenses can lead to progression of apical changes
 - Multicurve lens designs such as the Woodward design are suitable for moderate to advanced keratoconus.
 - DIL lenses are only useful for pellucid marginal degeneration and post graft eyes.
 - The McGuire lens is a modification of the Soper lens system.
- Which of the statements is false?
 - Softperm lenses were specially designed for keratoconus.
 - Neovascularisation is a common complication of Softperm hybrid lenses
 - The Rose K lens design incorporates three peripheral systems, standard, flat and steep
 - Kerasoft and Acuity Mark II are specially designed soft lenses for keratoconus
- Which of the following statements is true?
 - PMMA scleral lenses allow any kind of corneal irregularity to be corrected
 - PMMA scleral lenses are difficult to insert and remove
 - RGP scleral lenses are only useful for keratoconus
 - Softperm lenses have a long life span
- Which of the following statements is true?
 - Apical staining can result from a flat fitting lens
 - To reduce a tight mid-periphery, decrease the optic zone diameter, flatten the secondary or peripheral curves
 - Dimple veiling is a result of multiple tiny bubbles creeping under the lens
 - All of the above

An answer return form is included in this issue.

It should be completed and returned to:

CET initiatives (c-4087), OT, McMillan Scott, 9 Savoy Street, London, WC2E 7HR
 GU51 4DA by September 20 2006. Under no circumstances will forms received after this date be marked – the answers to the module will have been published in our September 22 2006 issue.

CET answers

Course code: c-4087

These are the correct answers to Module 5 Part 1, which appeared in our July 14, 2006 issue.

- Correct answer is B The promotion of pervaporation through a hydrogel lens is not thought to contribute towards the therapeutic action of a lens.
- Correct answer is D The ideal therapeutic lens for recurrent erosion syndrome has high oxygen permeability Low modulus of elasticity, low coefficient of resistance.
- Correct answer is A It is true that when selecting a therapeutic lens for a persistent epithelial defect that silicone hydrogel lenses should be the first choice.
- Correct answer is D A lens which causes pervaporation has not been proposed in selecting a lens for an eye with a corneal laceration and flat anterior chamber.
- Correct answer is C A scleral lens is not used to prevent symblepharon from ocular pemphigoid.
- Correct answer is C A silicone hydrogel with a low modulus of elasticity is the lens of first choice to help reform a collapsed anterior chamber following radial keratotomy.
- Correct answer is D A Scleral lens is most likely to offer protection from severe entropion.
- Correct answer is D The first choice for correcting a ptosis is a Scleral lens.
- Correct answer is A The first choice therapeutic lens for superior limbic keratitis is a 20.0 mm hydrogel lens.
- Correct answer is A The first choice contact lens for pain relief in filamentary keratitis is currently Hydrogel lens.
- Correct answer is A A Hydrogel lens is least likely to be selected in trichiasis from the four lenses shown.
- Correct answer is B A lens with the diameter of 12mm to 14mm is not typically selected for cases with a leaking trabeculectomy.